

XI CONGRESSO NAZIONALE SISAV

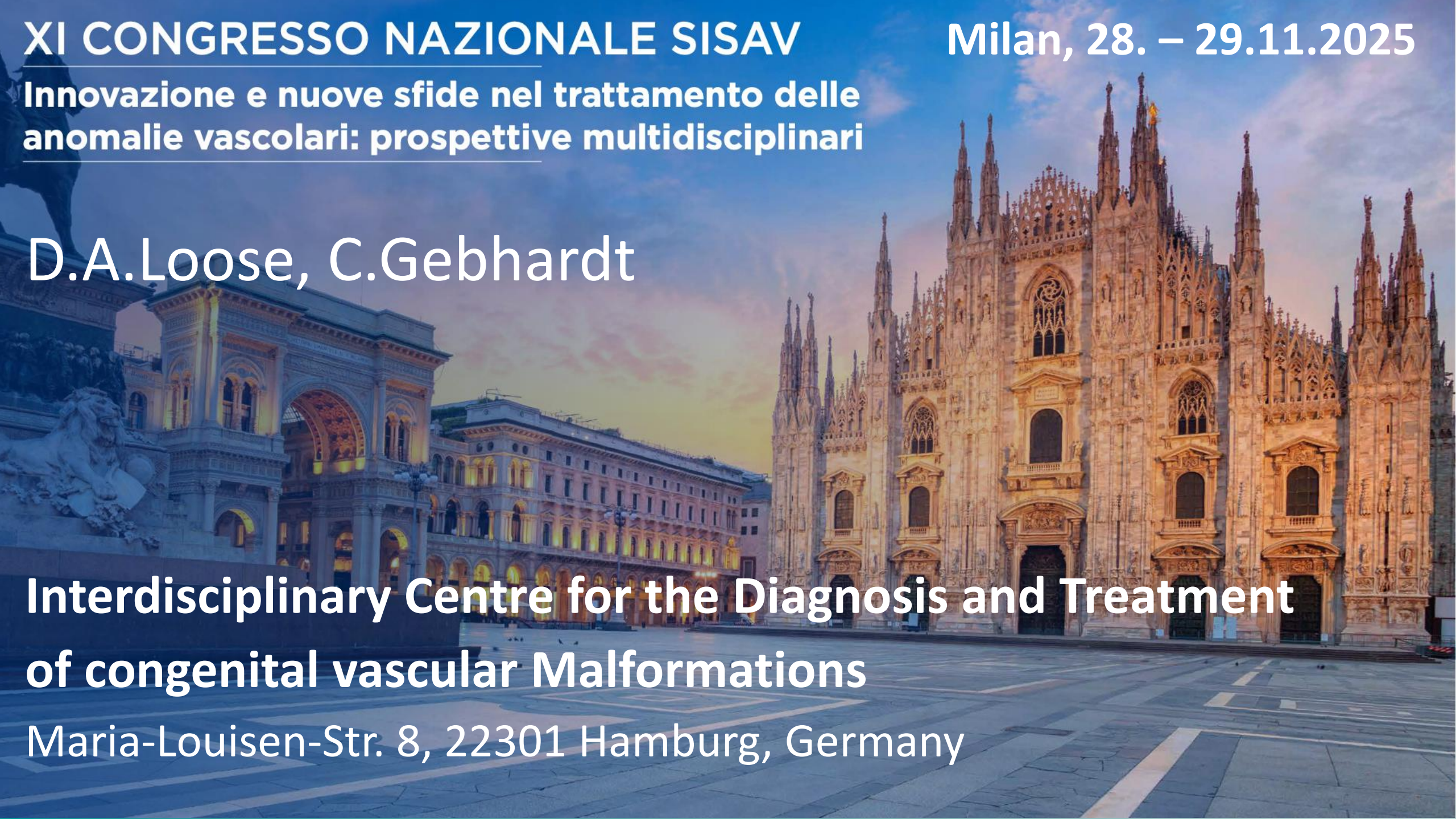Milan, 28. – 29.11.2025

**Innovazione e nuove sfide nel trattamento delle
anomalie vascolari: prospettive multidisciplinari**

D.A.Loose, C.Gebhardt


**Interdisciplinary Centre for the Diagnosis and Treatment
of congenital vascular Malformations**

Maria-Louisen-Str. 8, 22301 Hamburg, Germany

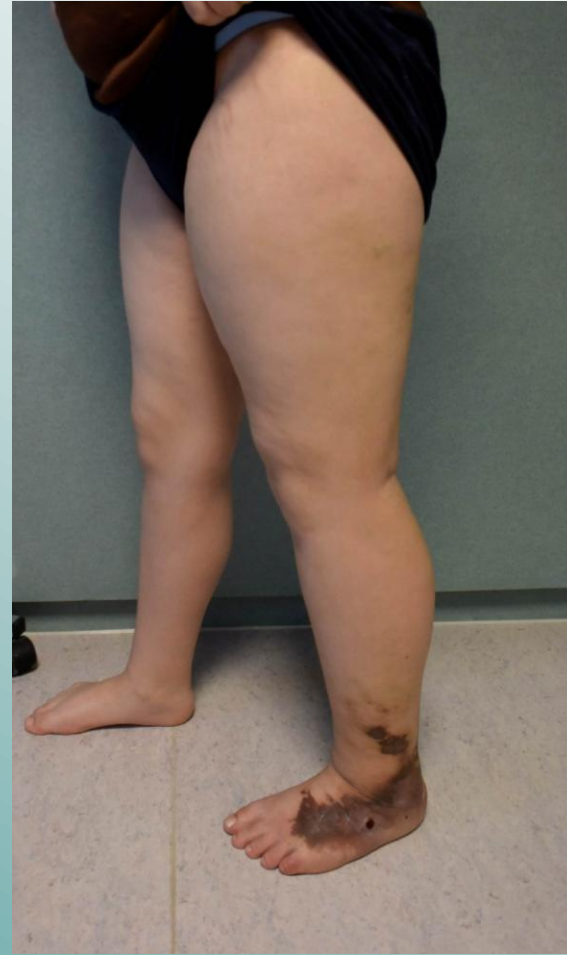
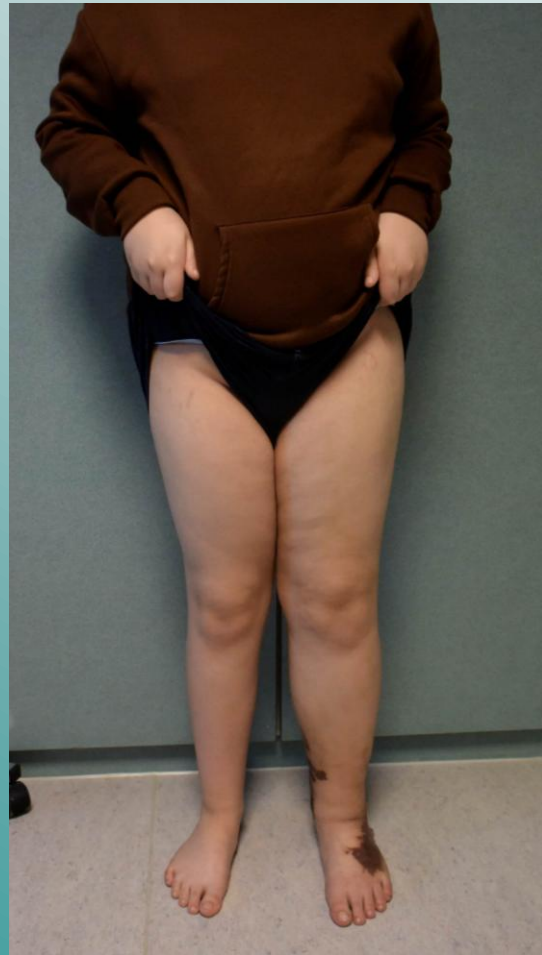
Congenital Vascular Malformations of the Foot:

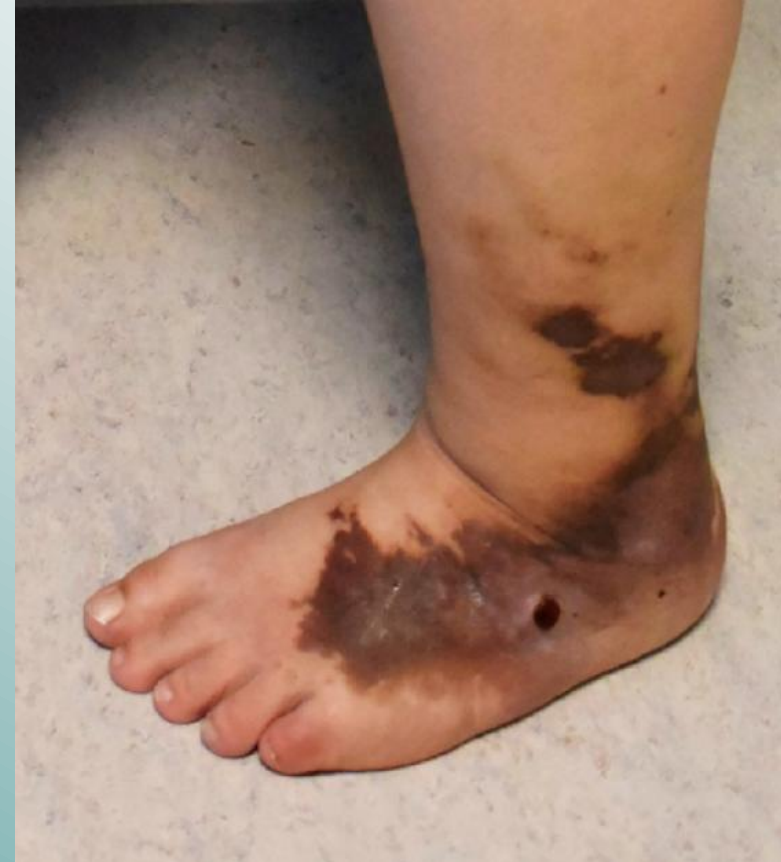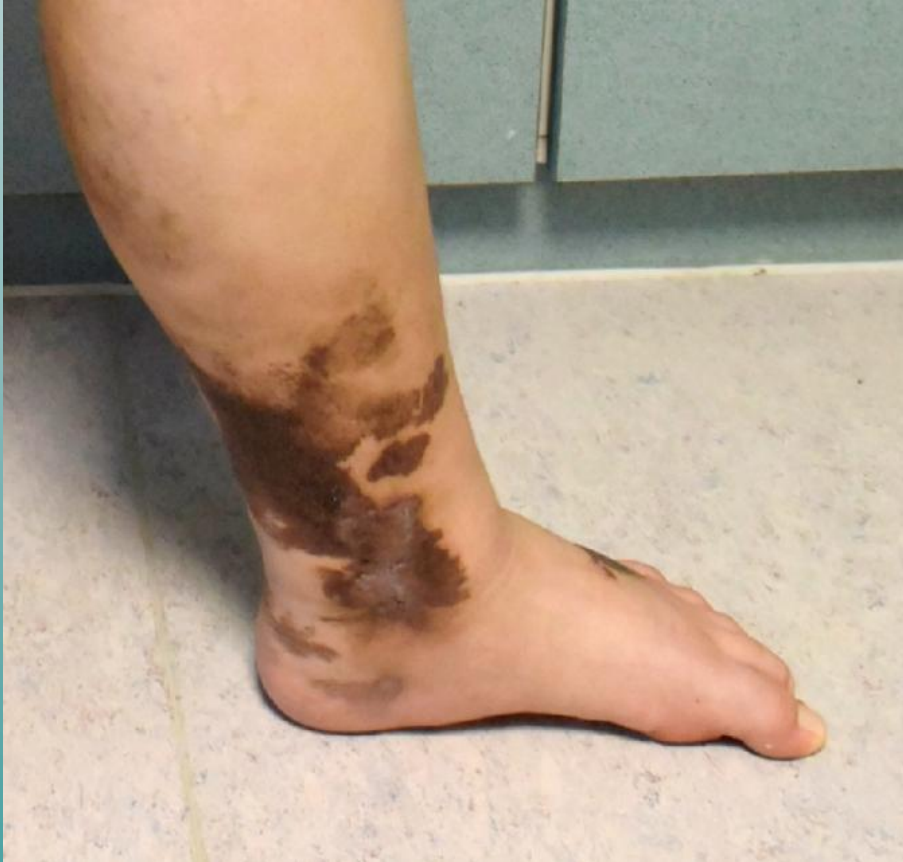Reasonable and Efficient Treatment Approaches



12-year-old boy seen by several doctors over a period of more than ten years, at last diagnosed with "Klippel-Trenaunay-Syndrome" explaining "no possibility of treatment"



1.) Diagnostic steps, 2.) Classification, 3.) Treatment possibilities



Hamburger Klassifikation (1988) ISSVA Classification (1996)

Vascular Pathology

```
graph TD; VP[Vascular Pathology] --> VT[Vascular Tumors]; VP --> CVM[Congenital Vascular MALFORMATIONS];
```

Vascular Tumors

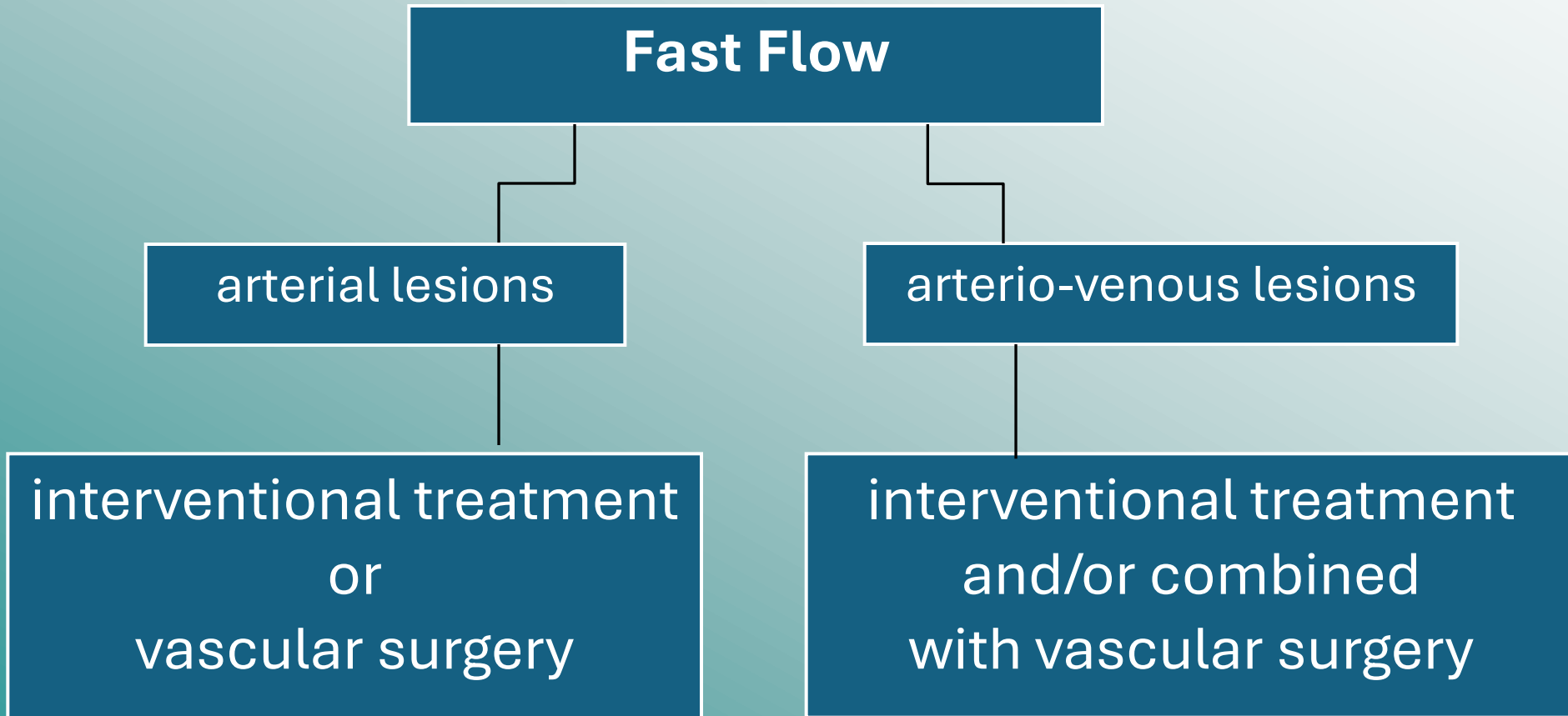
- Hemangiomas
- others

Congenital Vascular MALFORMATIONS

- **Slow flow** (capillary, venous, lymphatic, mixed)
- **Fast flow**
 - exclusively arterial
 - arterio-venous fistulas

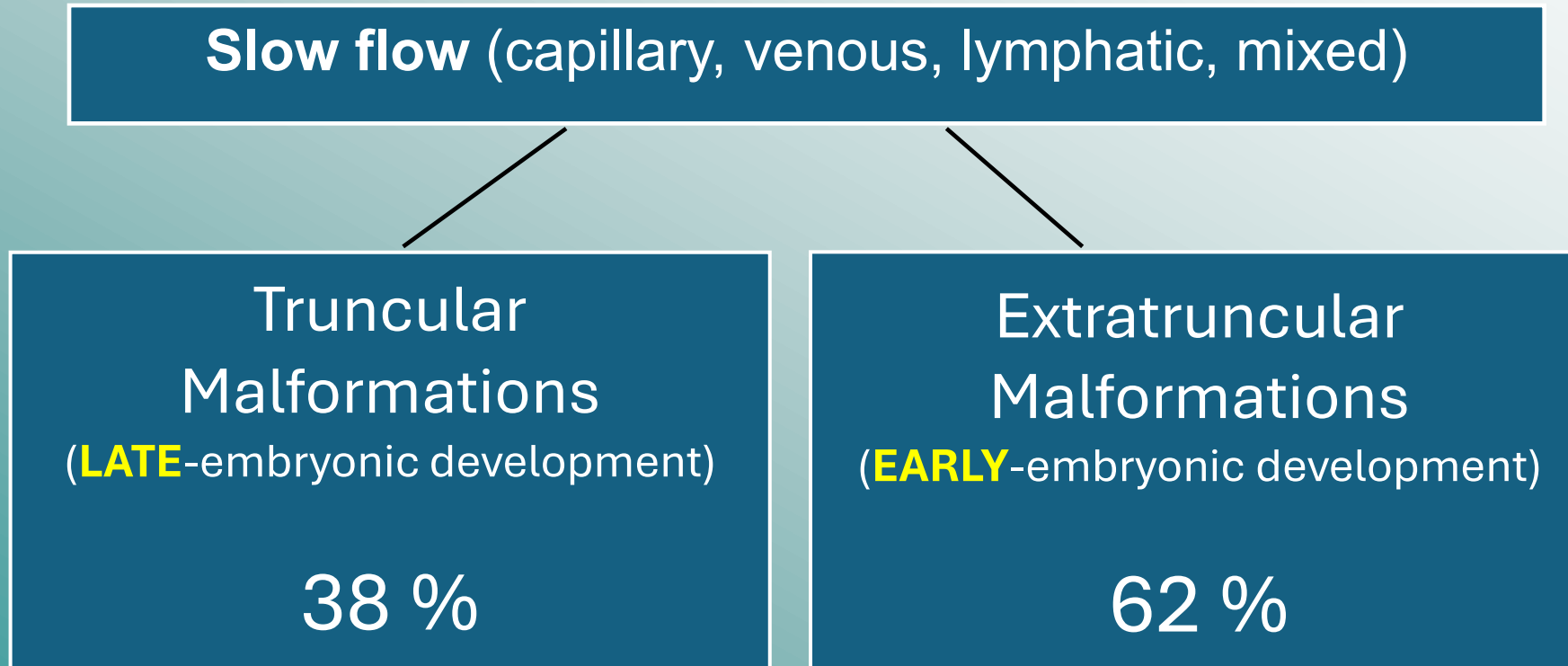
Interdisciplinary therapeutic options for arterial or arterio-venous malformations

(International Consensus Statement 2009)



Classification of Venous and Lymphatic Malformation Types

(International Consensus Statement 2009)



1000 newborns per year with venous malformations in Germany
(Achse e.V. – Alliance of Chronic Rare Diseases)

Routine?

Venous Malformations



hence sclerotherapy?

WRONG!!!!

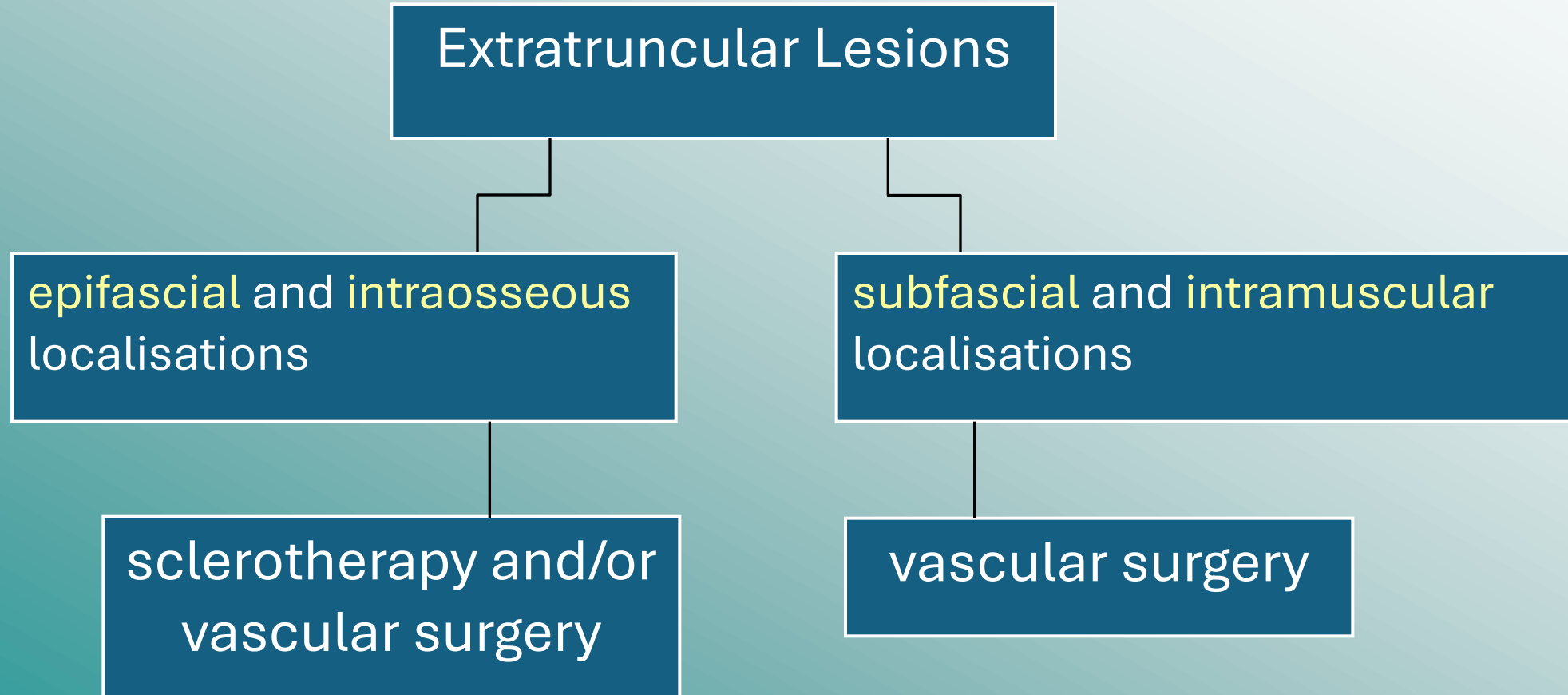


remember: risk of pulmonary embolism!

A comprehensive assessment of **both**: venous and arterial systems is crucial **prior** to determining any treatment strategy.

Interdisciplinary therapeutic options for venous malformations

(International Consensus Statement 2009)



Treatment Strategy

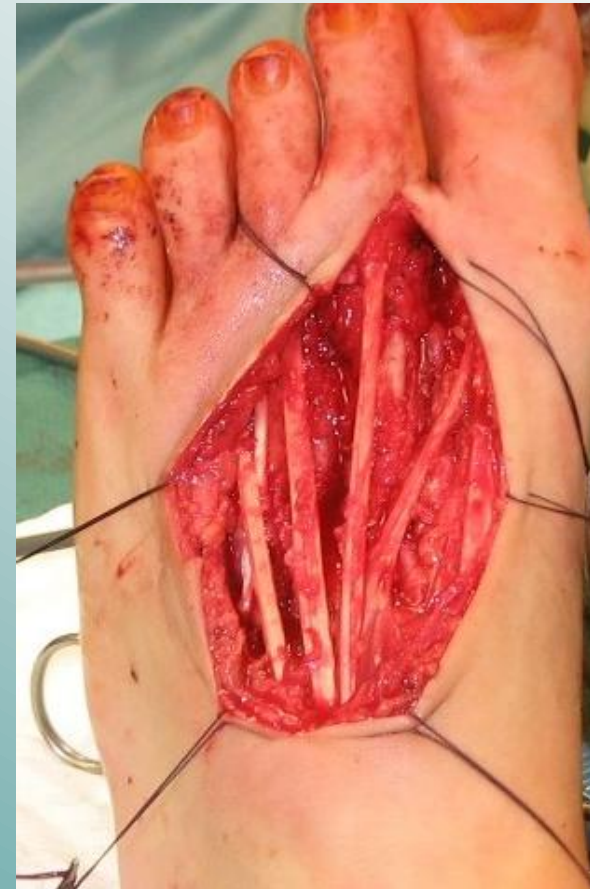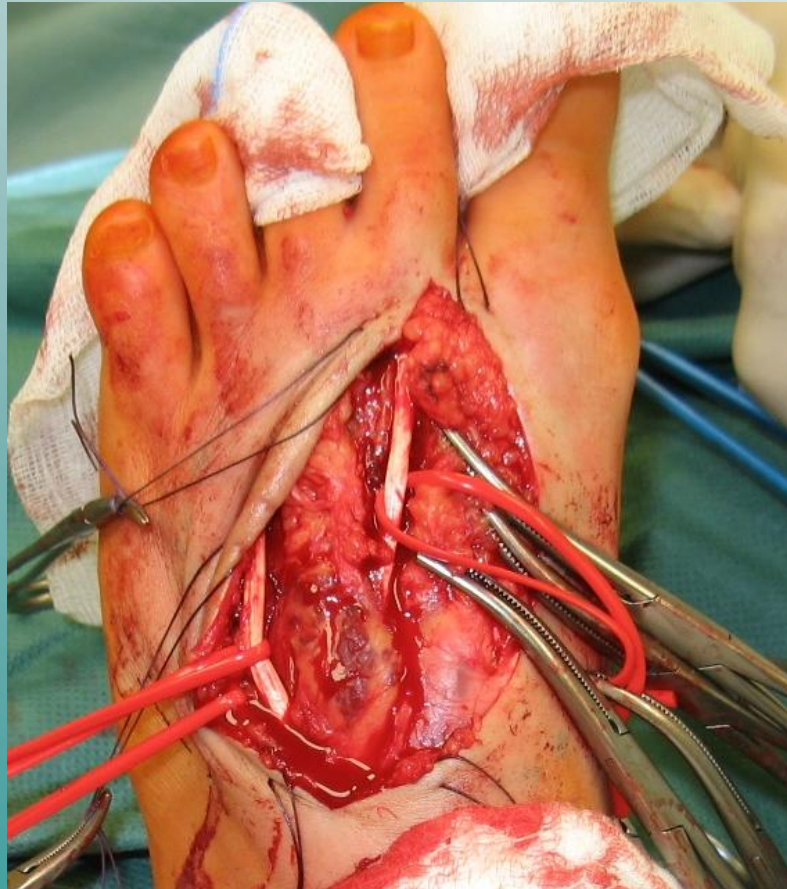Vascular Surgery:

- super selective extirpation of malformed veins in epifascial and subfascial localizations

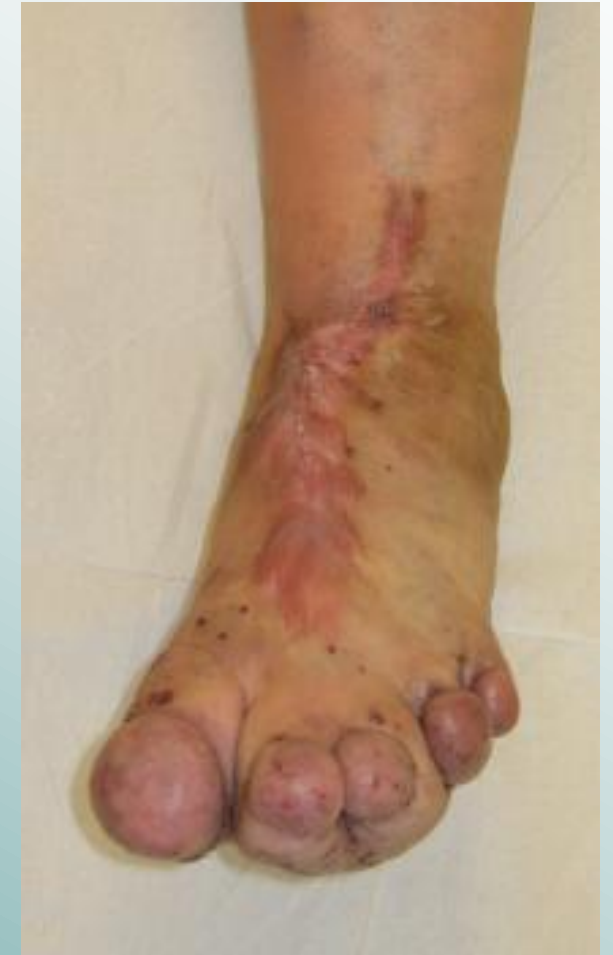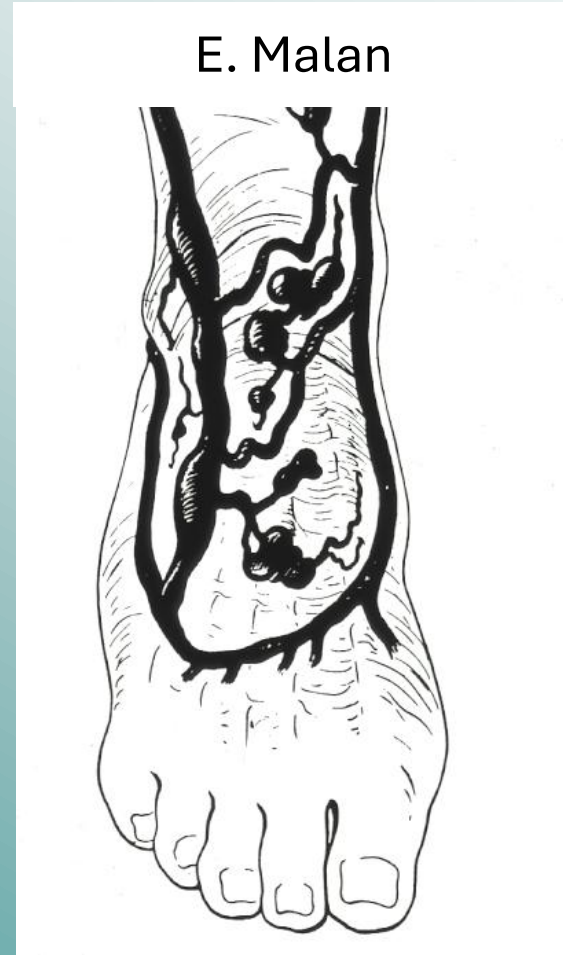
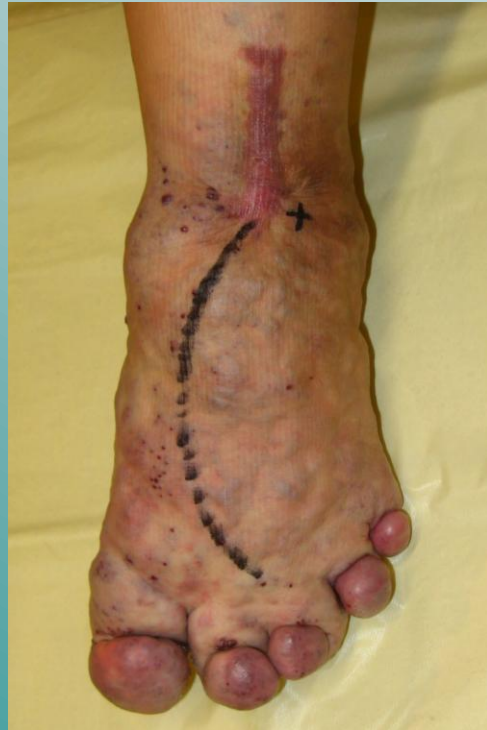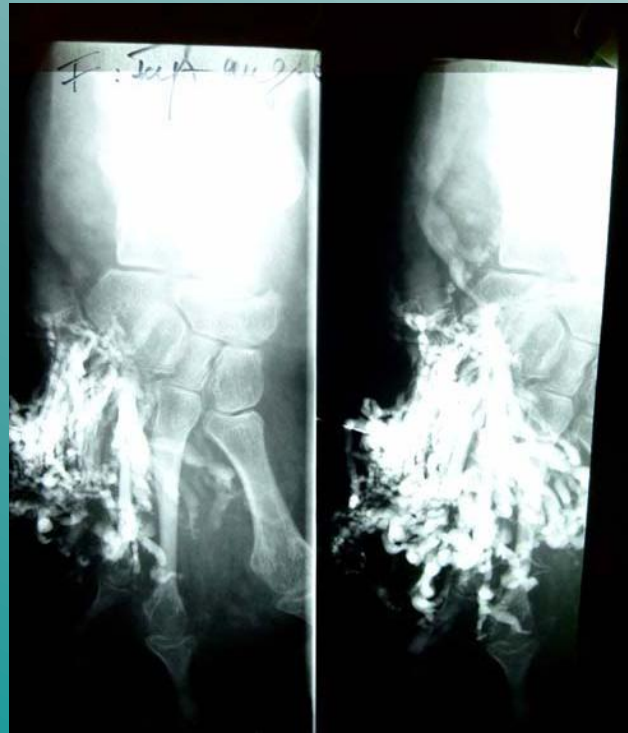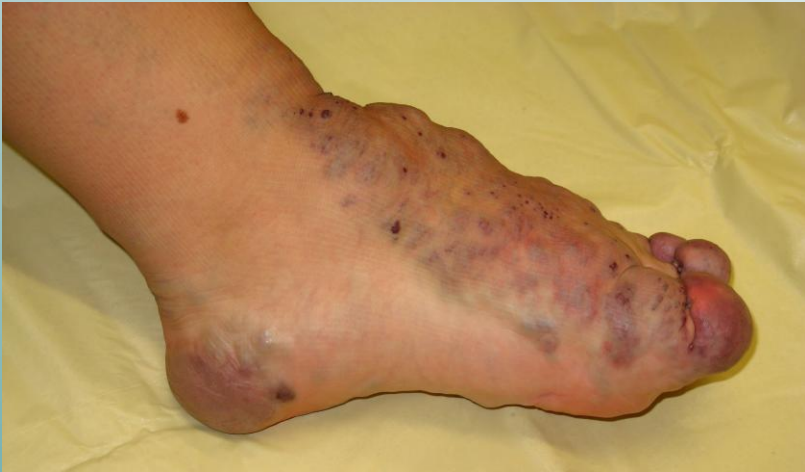Sclerotherapy of small regions and extent:

- foam sclerotherapy
- alcohol sclerotherapy - as the sole or additional therapy of superficial malformed veins, if no av fistulas are present (Cabrera et al. 2009; Yakes et al. 2025)
- Bleomycin electrosclerotherapy? - **in selected cases only** (Miller et al. 2025)

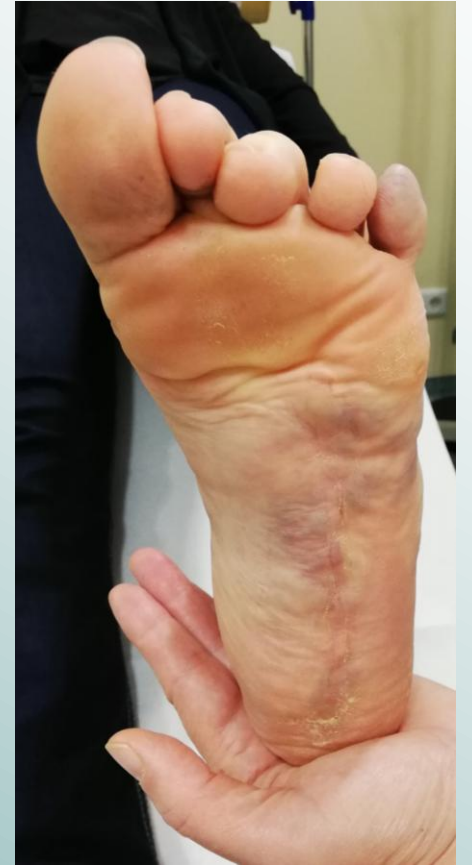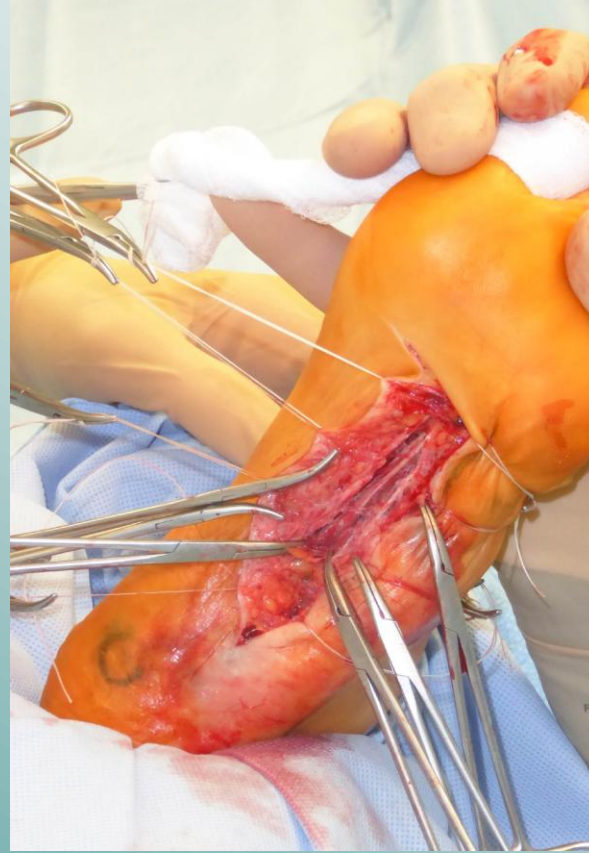
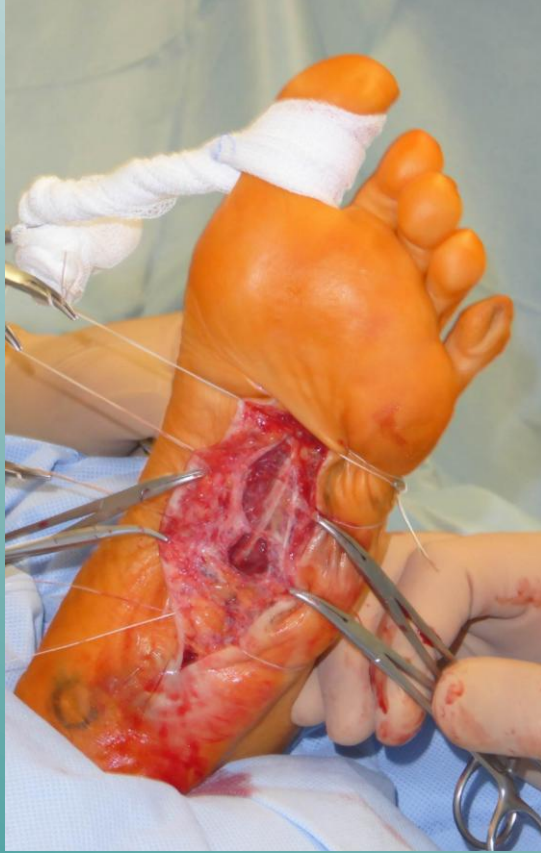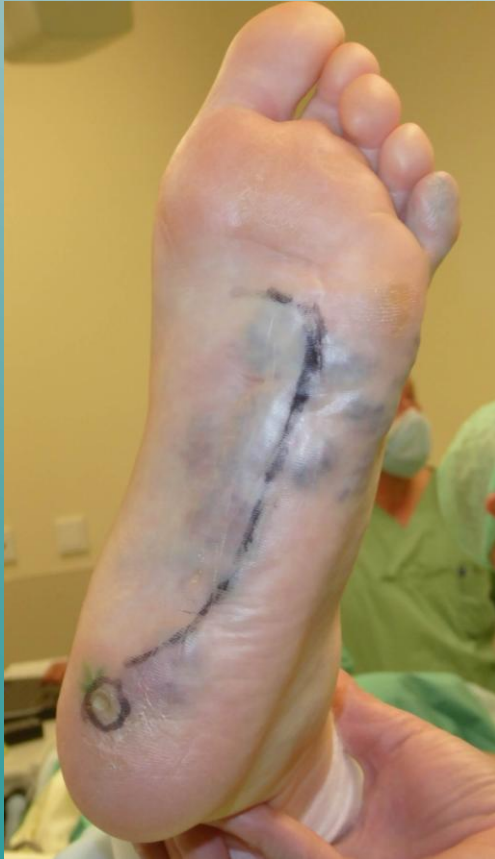super selective extirpation of malformed veins
in epifascial **and subfascial** regions



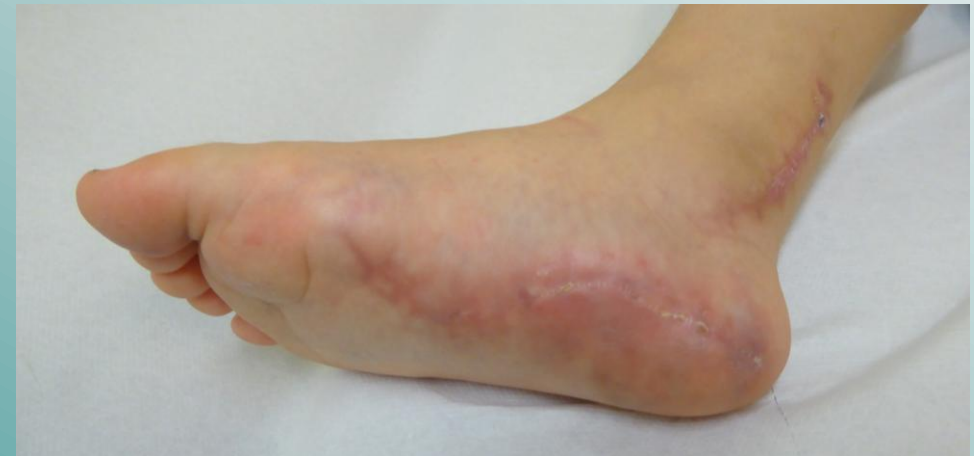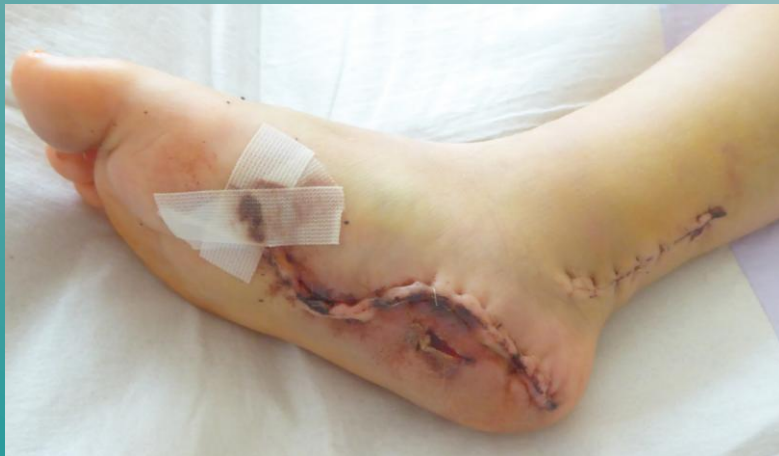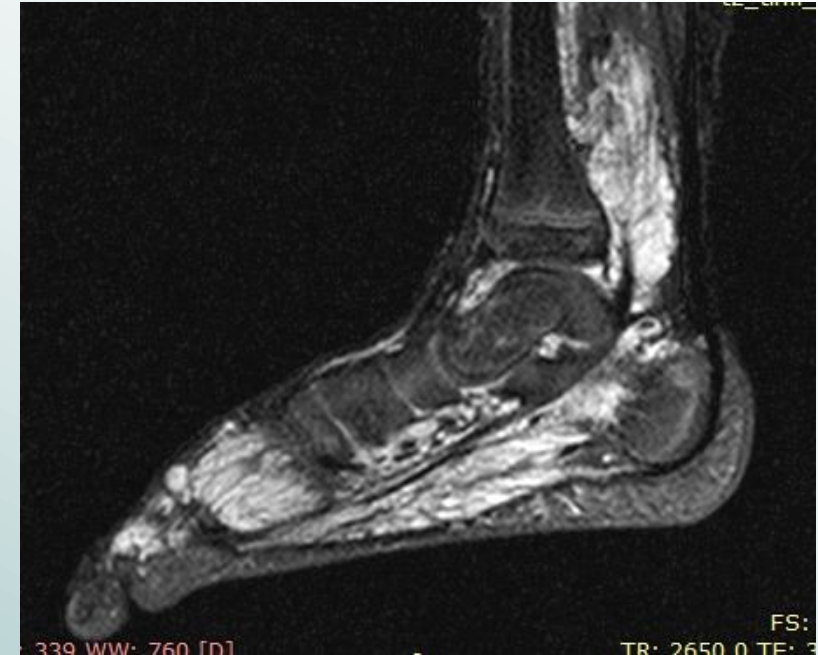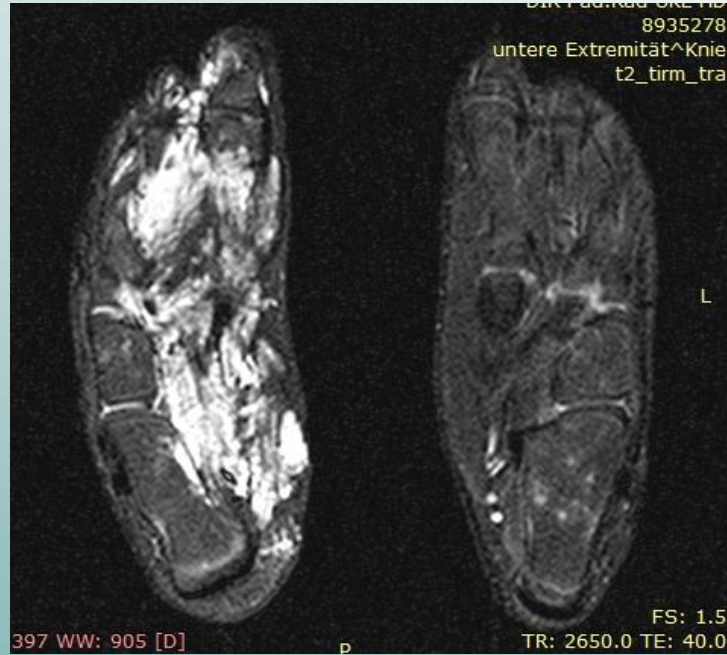
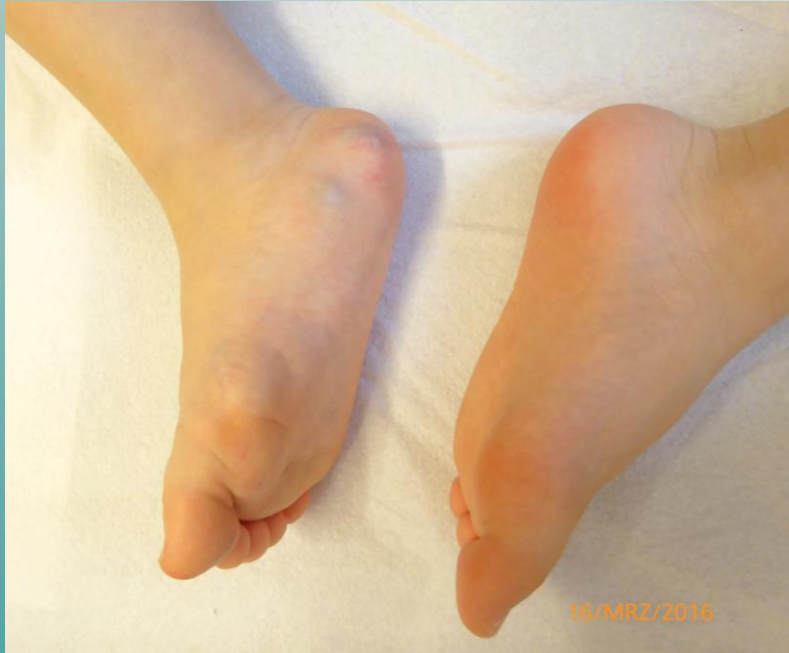Extended venous malformations at the dorsum of the foot of a ten-year-old girl



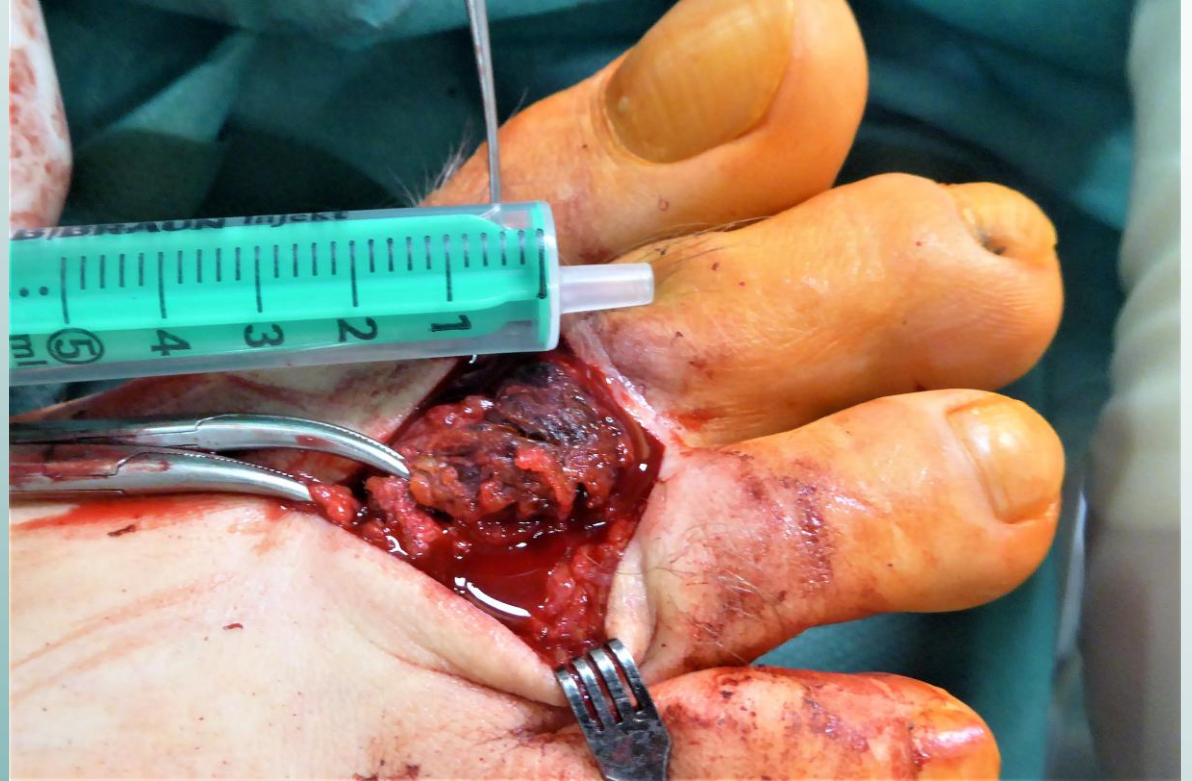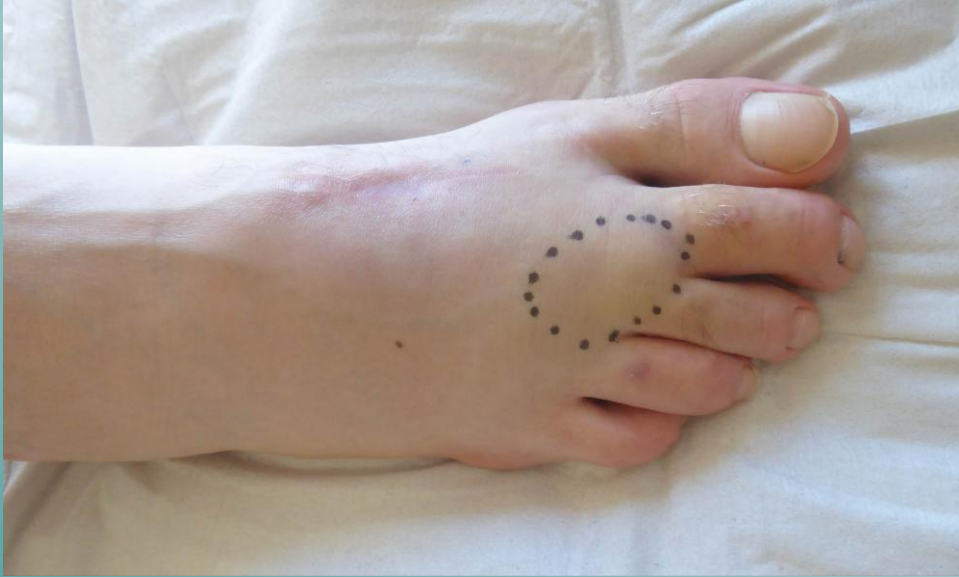Extended extirpation of venous malformations
epifascial **and subfascial** at the planta pedis



Extensive extirpation of venous malformations epifascial **and** subfascial at the planta pedis of a four-year-old boy

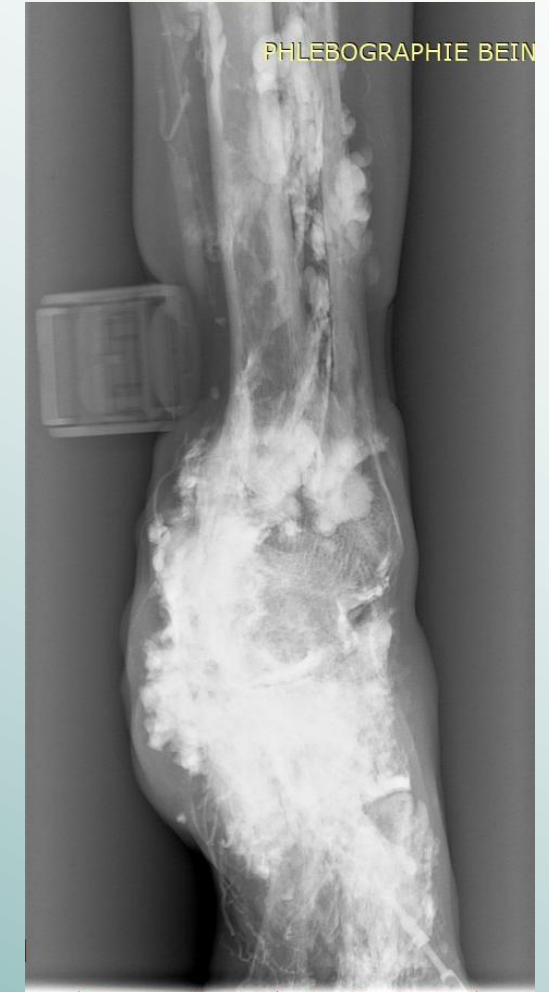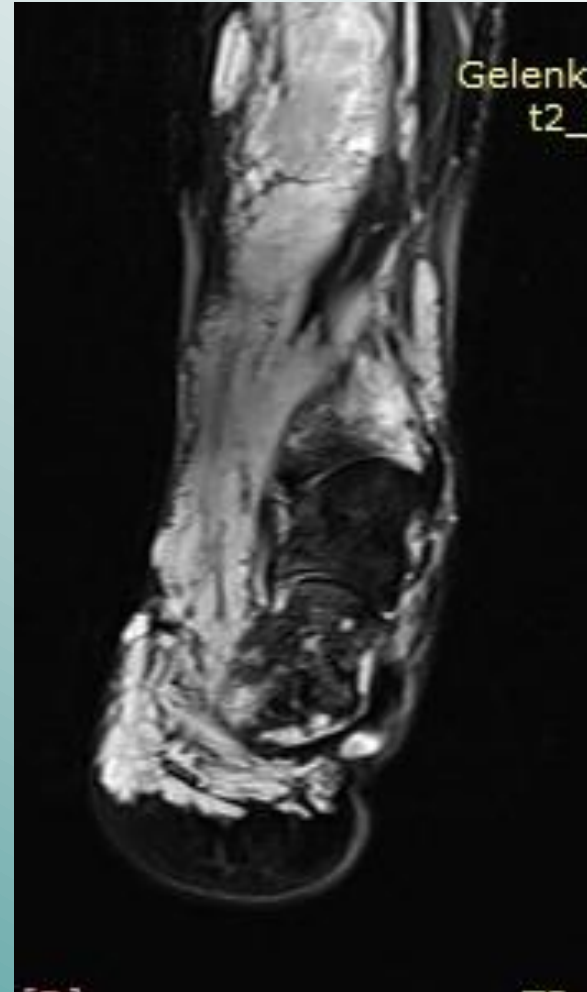

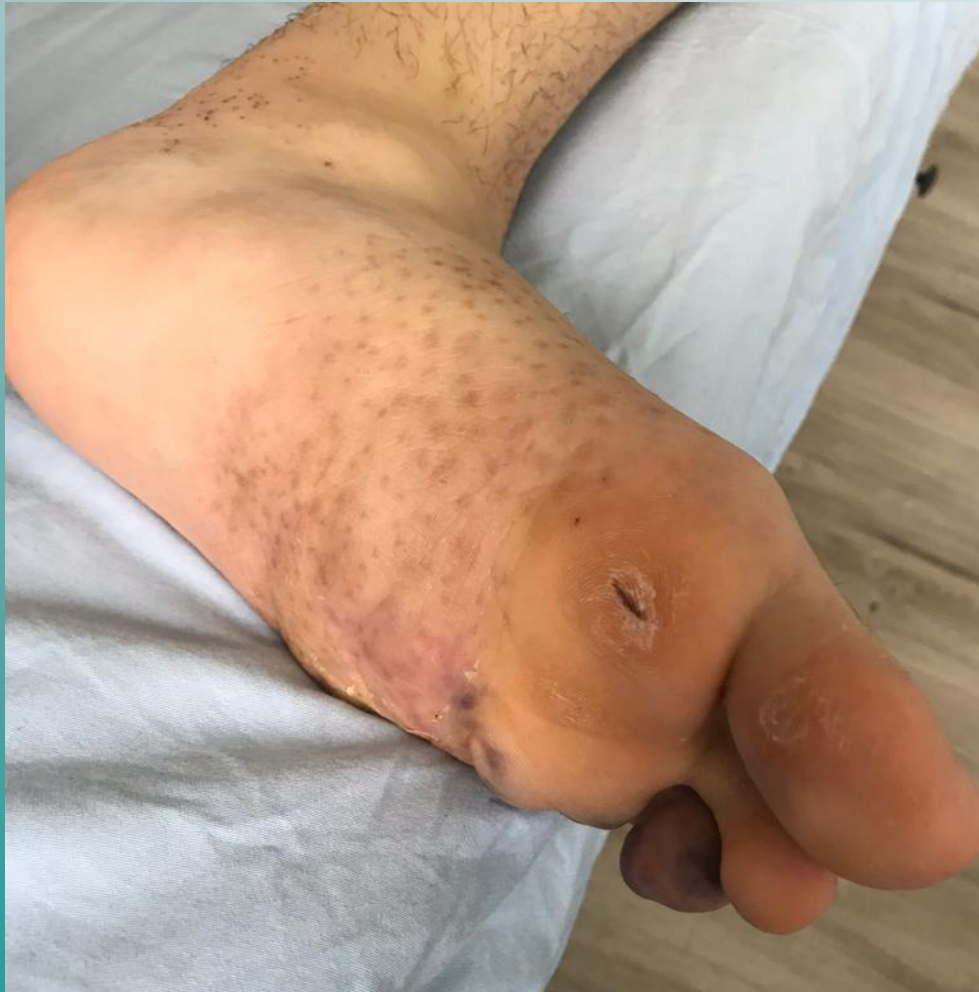
Localized infiltrating lymphatic malformation: total extirpation by vascular surgery *



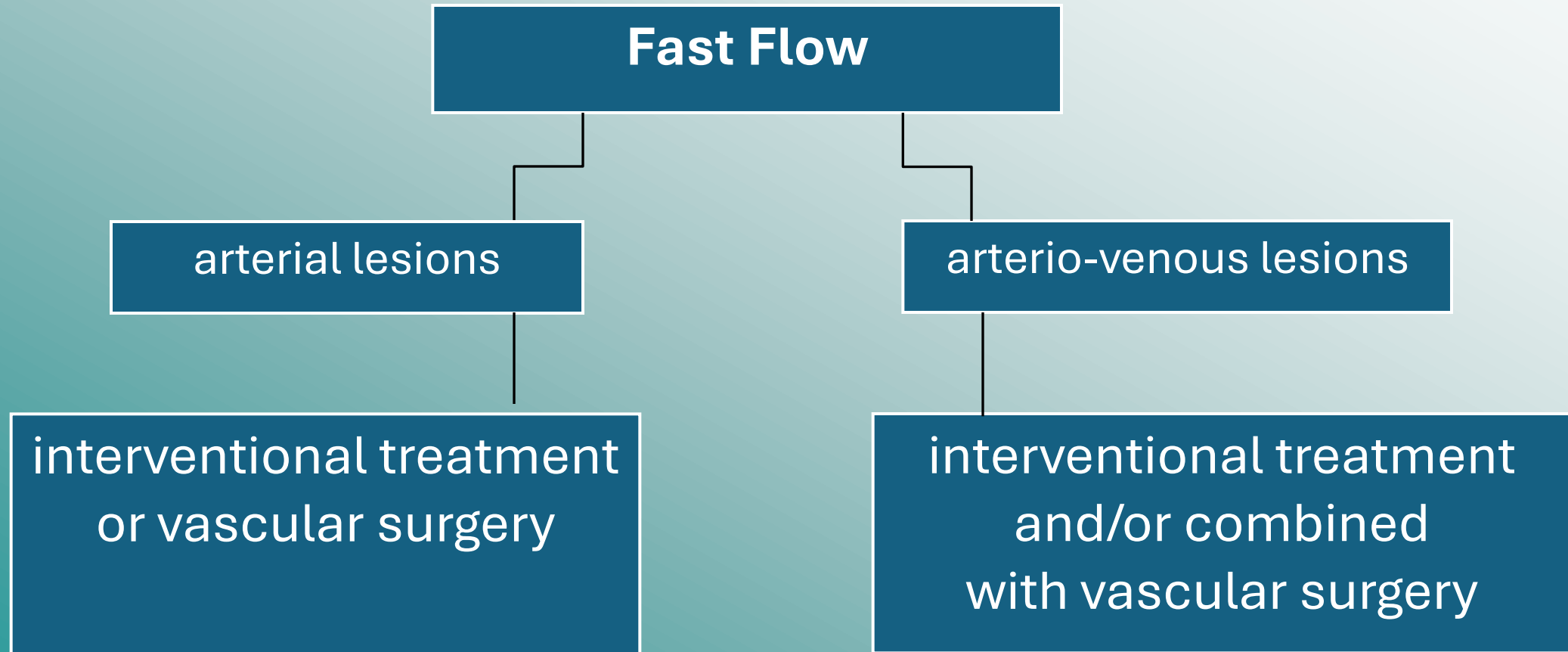
* the sclerotreatment with Picibanil (technique according to *N. Ghaffarpour* 2018) failed in this case

Situation after treatment of an infiltrating venous malformation by two Bleomycin electrosclectrotherapy treatments and consequently worsening of pain syndrome!

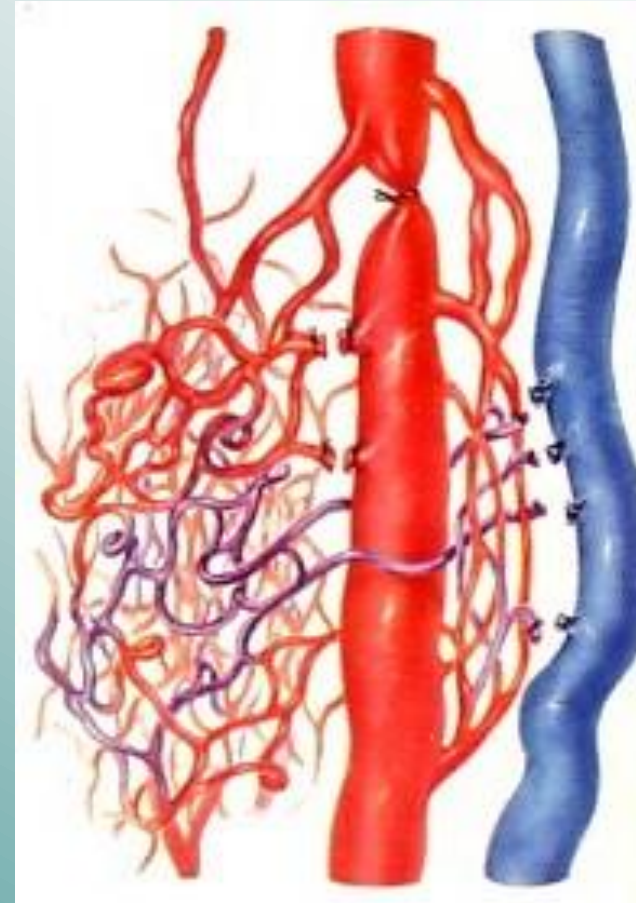
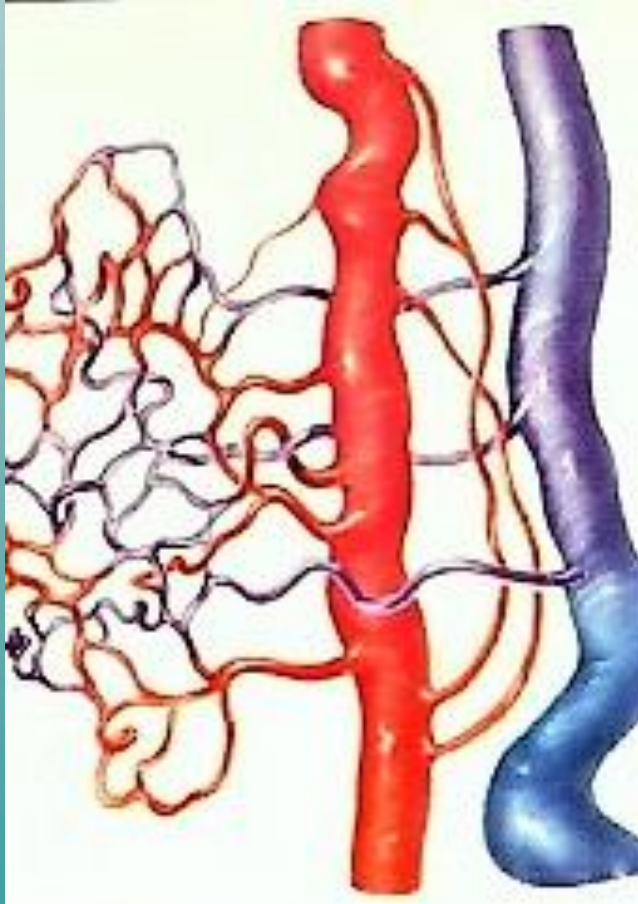


Interdisciplinary therapeutic options for arterial or arterio-venous malformations

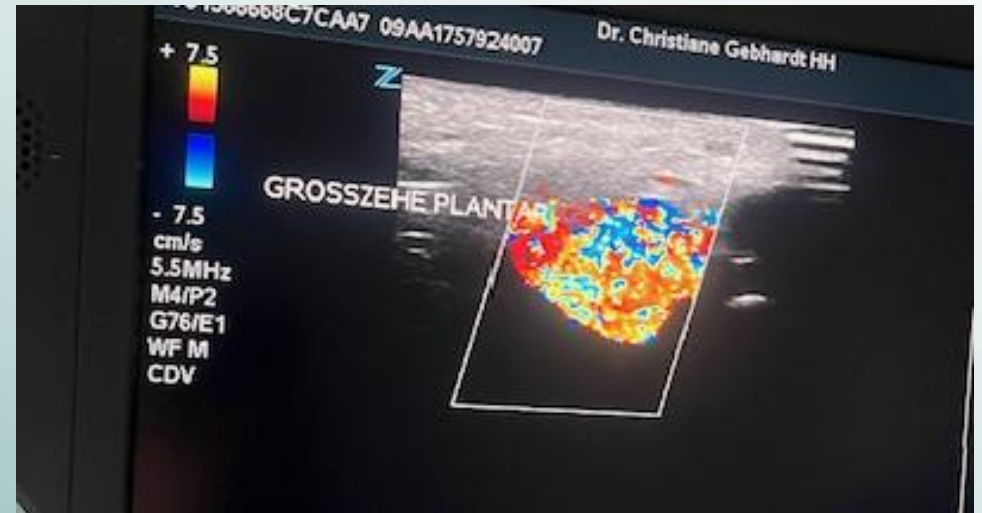
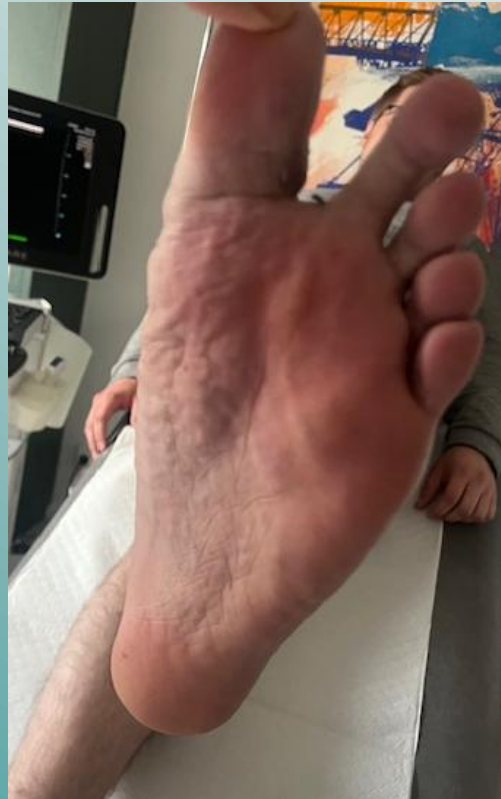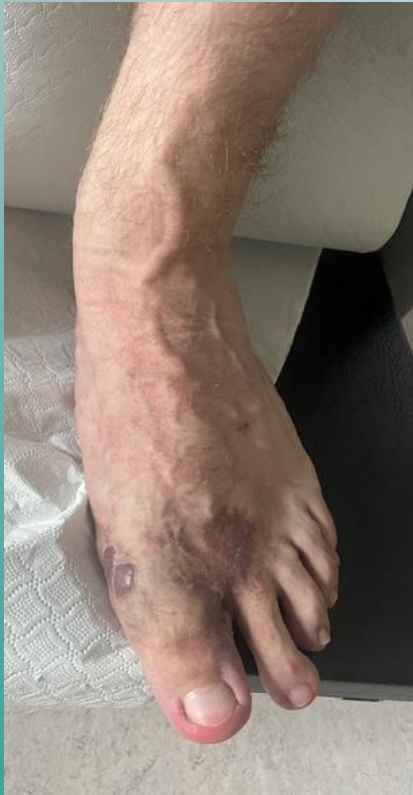(International Consensus Statement 2009)



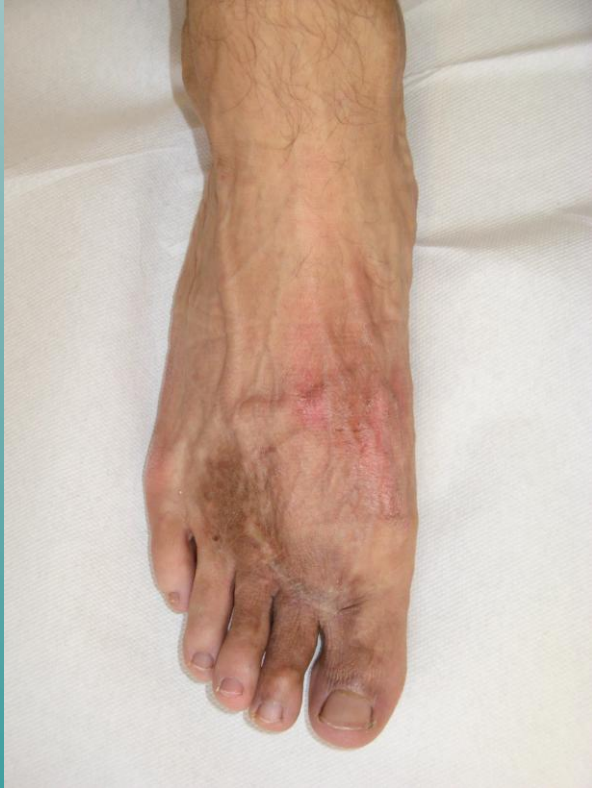Schematic drawings by *Edmondo Malan* (1964)
demonstrating the surgical treatment of av-malformations



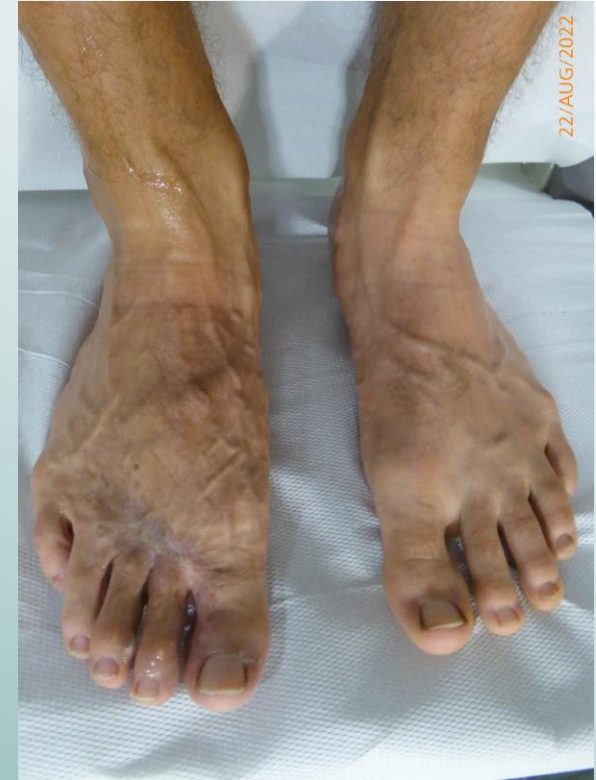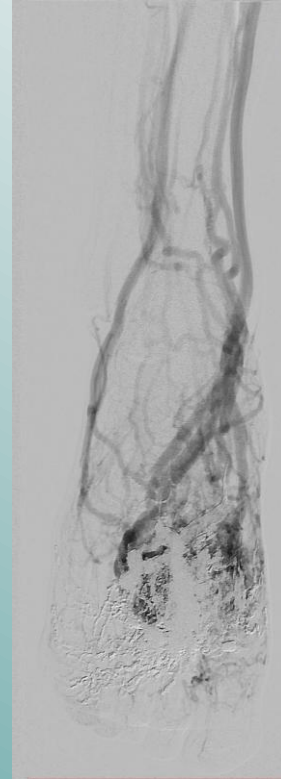
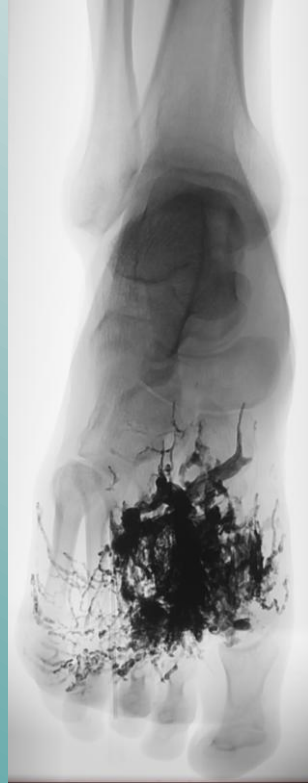Extratrukular arterio-venous malformation at the forefoot
Standard treatment: interventional embolization of the av-fistulas



Av-malformation of the right forefoot 12 years after repeated interventional treatment sessions

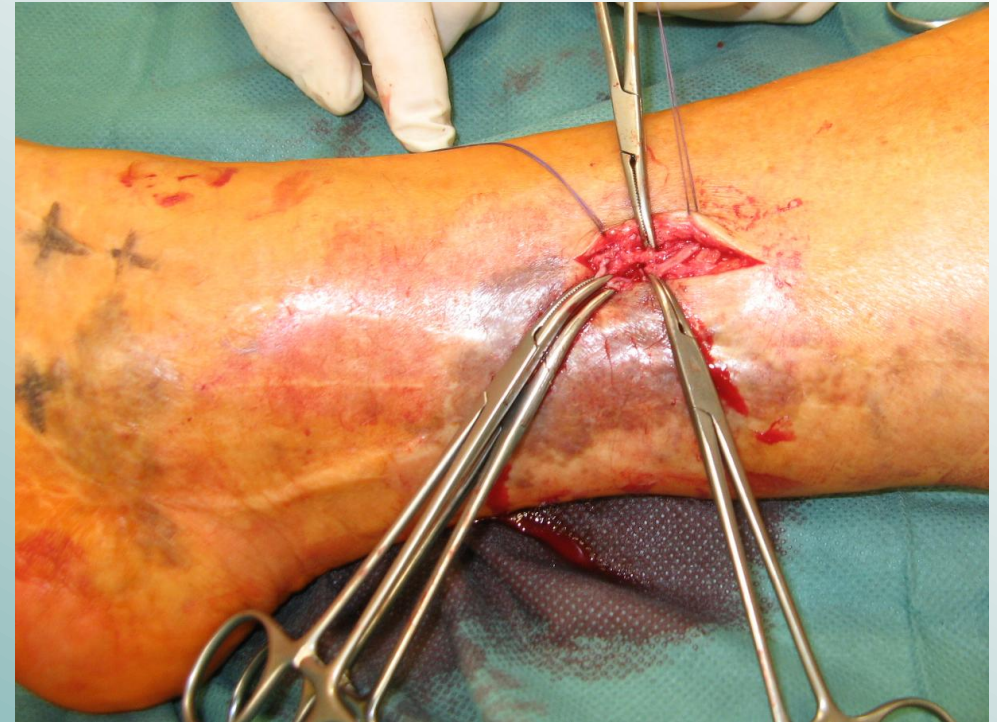
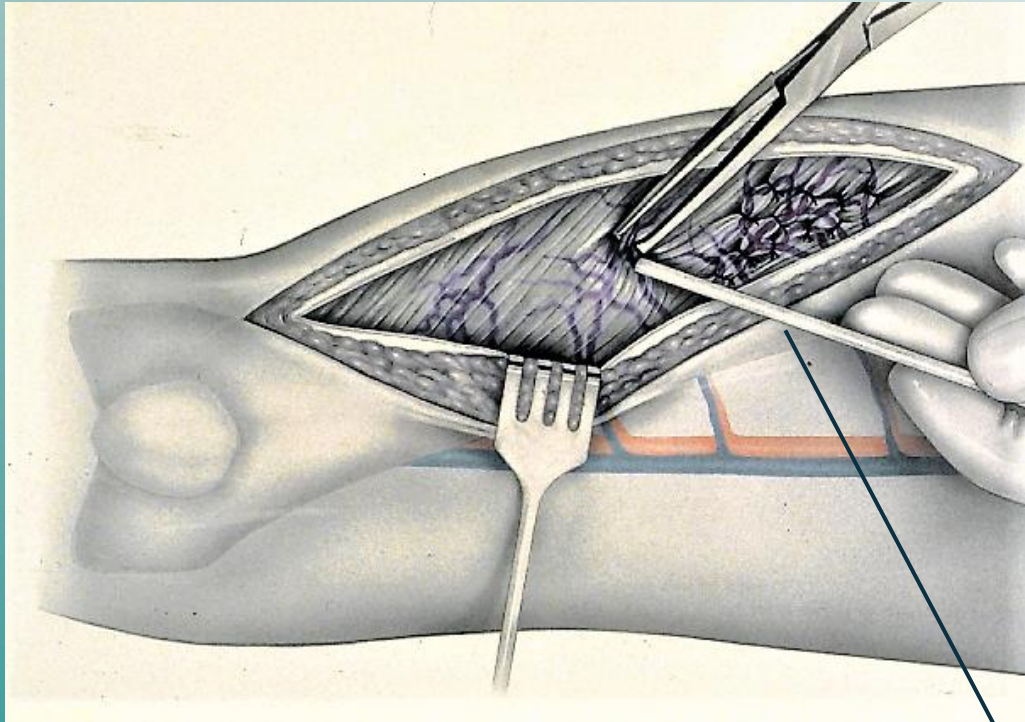


2010



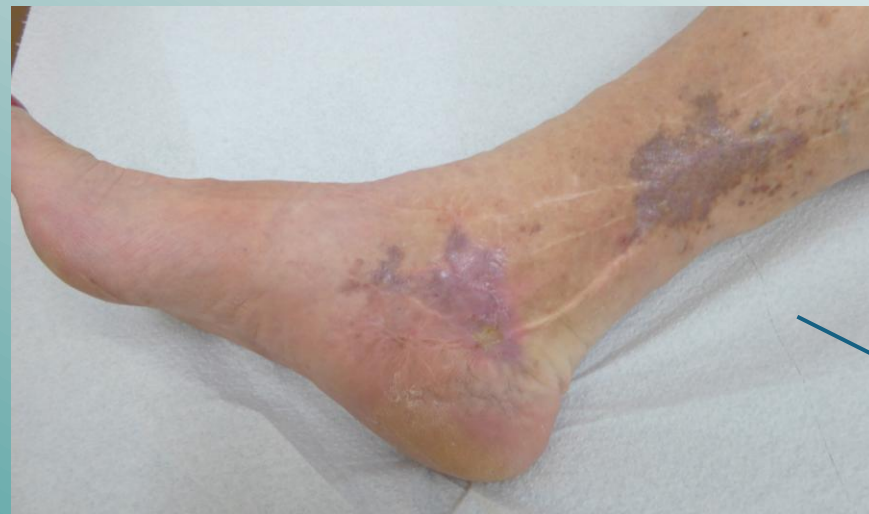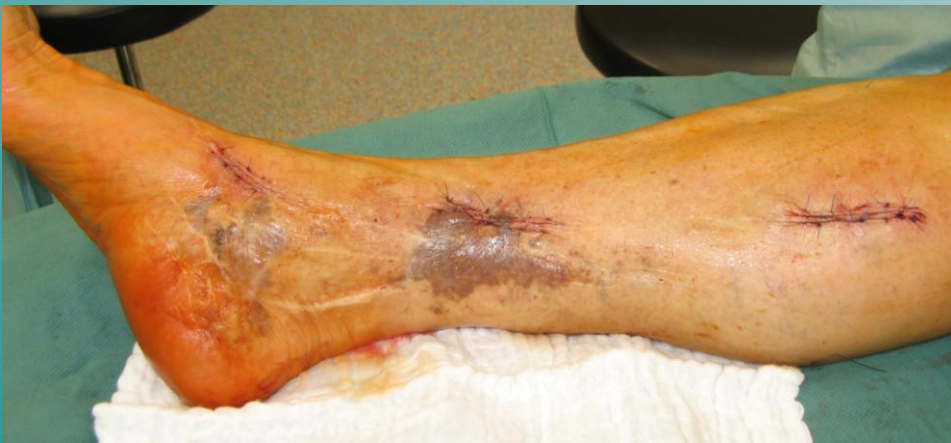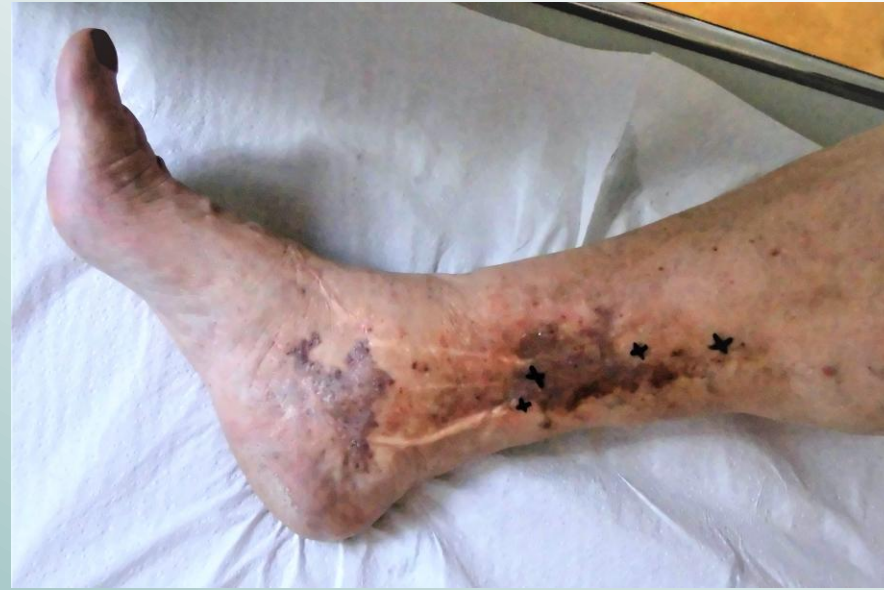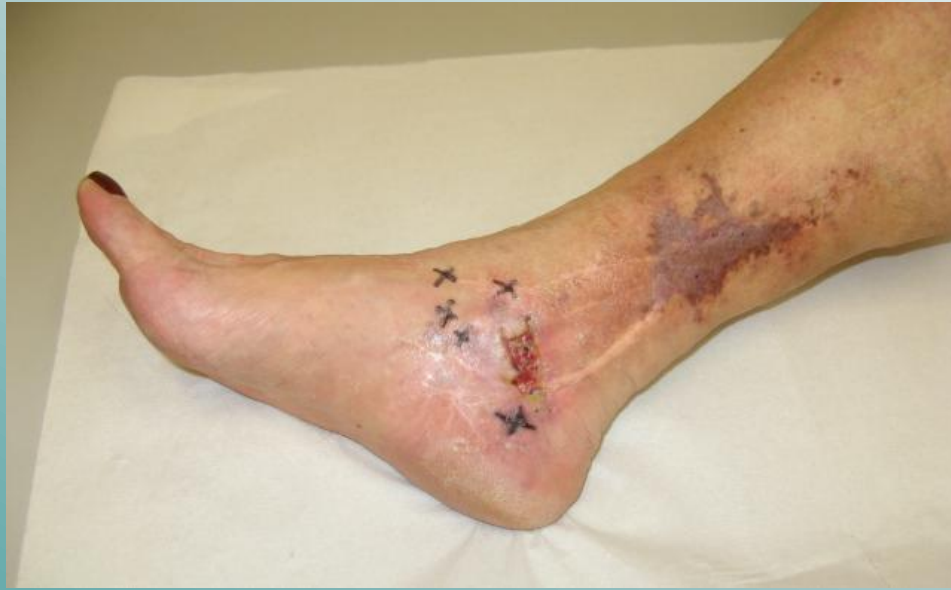2022

When interventional treatment is not sufficient, ultrasound identification of av-fistulas and surgical occlusion is possible.



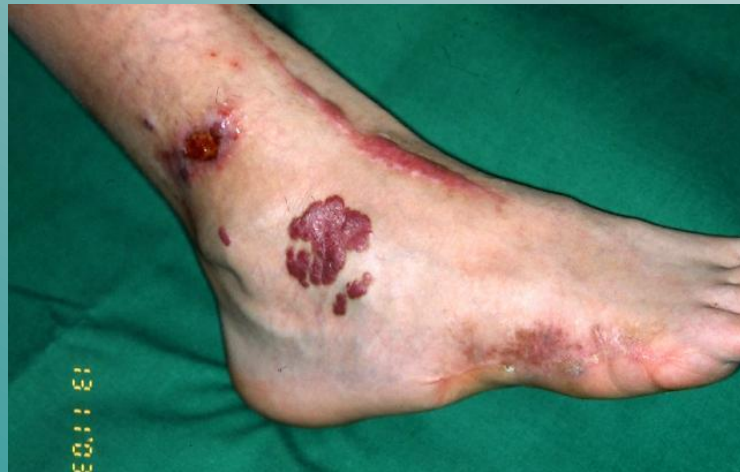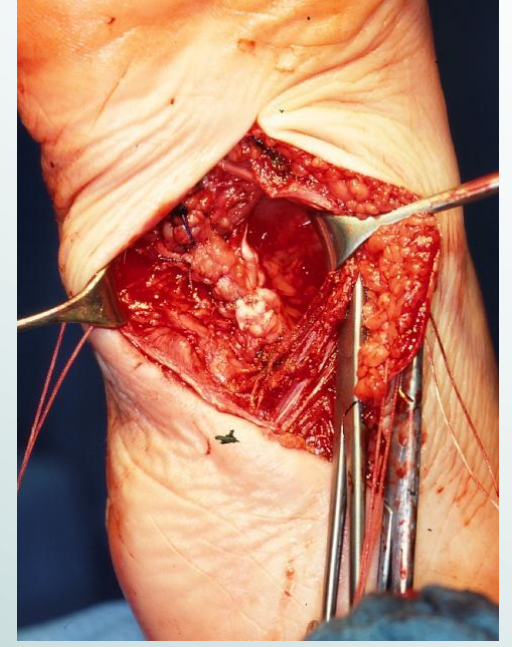
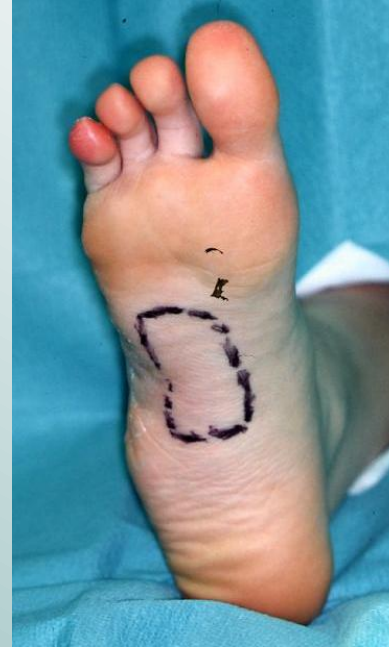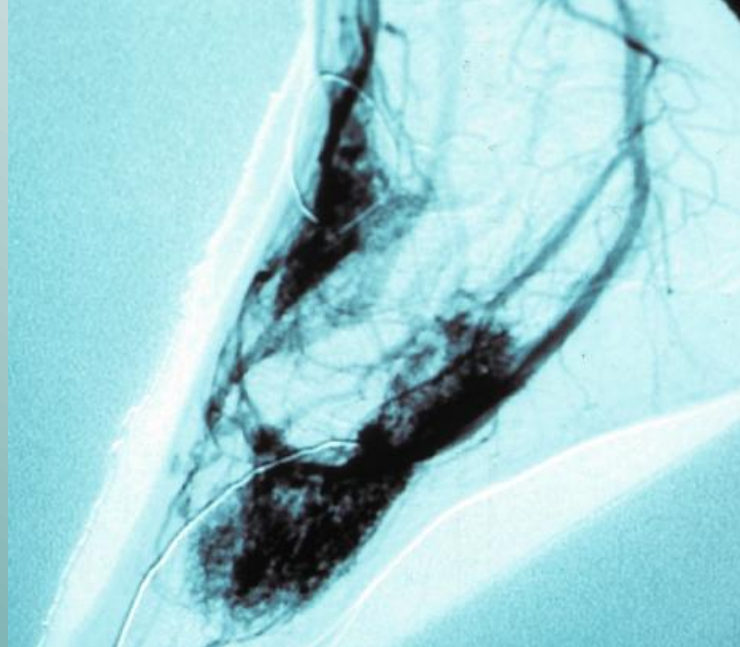
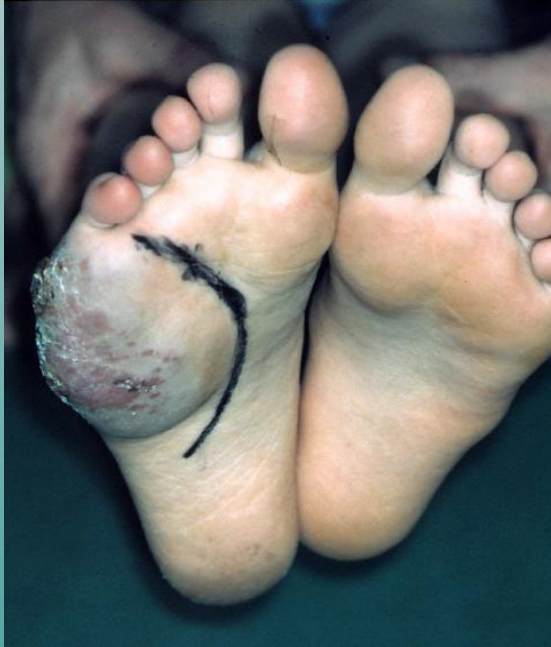Mini ultrasound sond

Intermediate and final results of the same patient



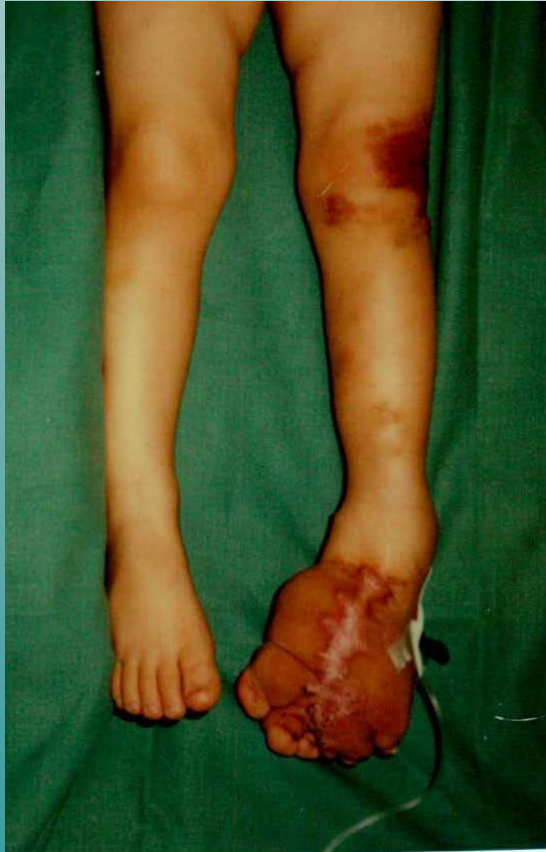15-years later

12-year-old boy with av-malformations of the dorsum and the planta of the foot

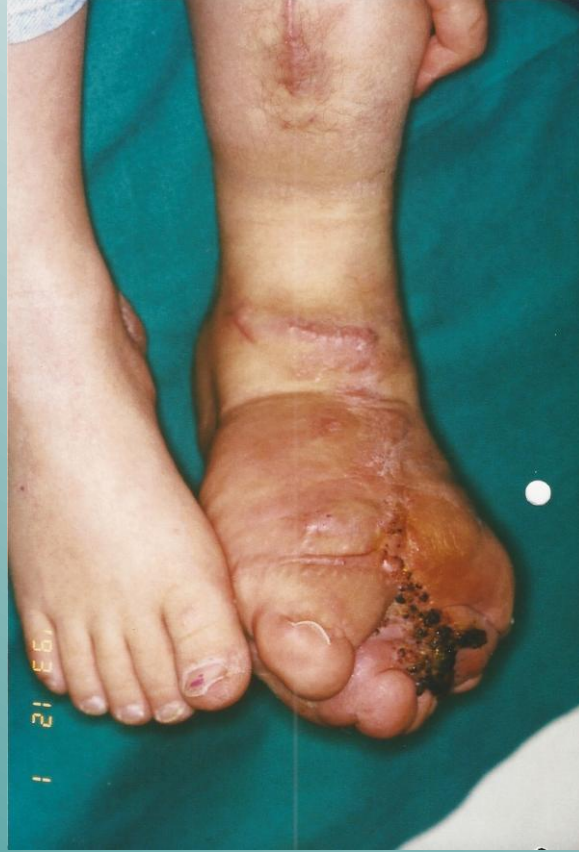

Situation after several steps of interventional treatment and of vascular surgery

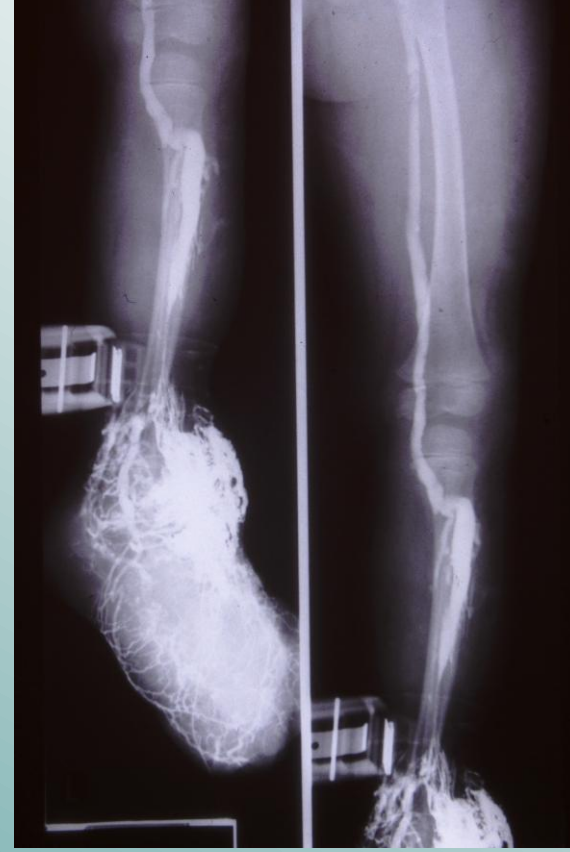
Hemolymphatic malformation of the whole left foot



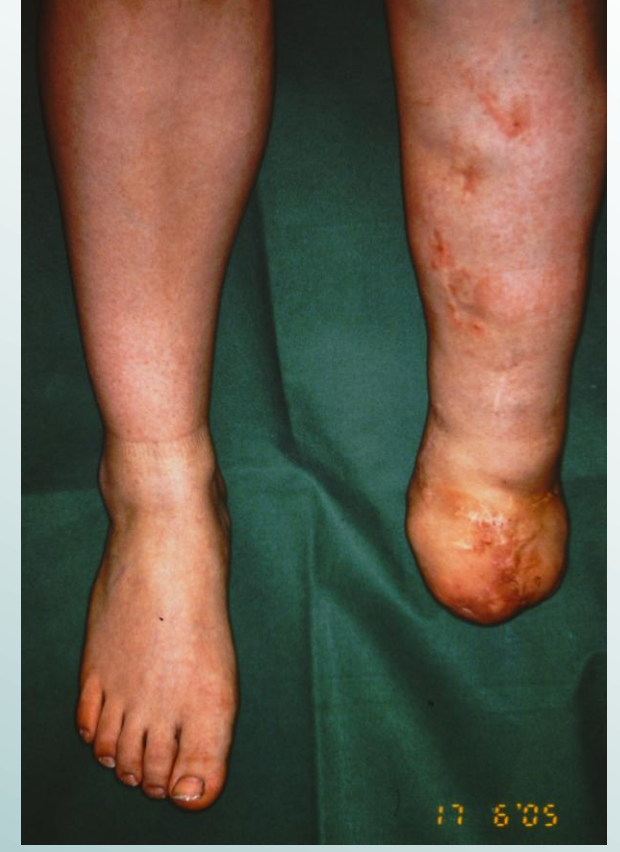age: 2 years



age: 3 years

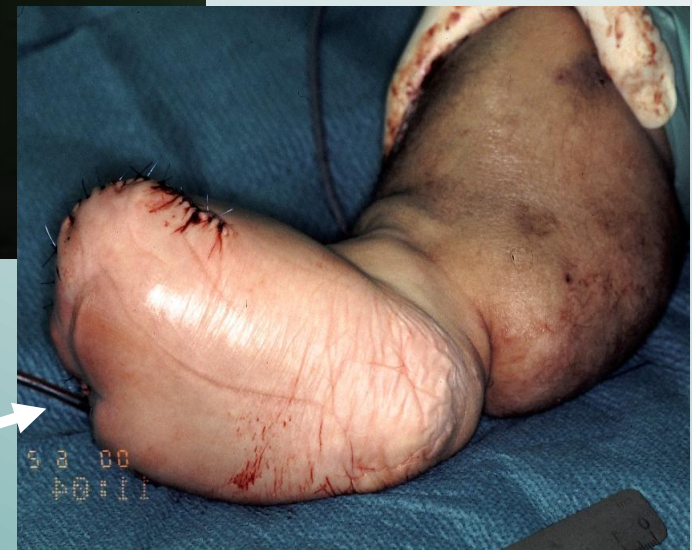
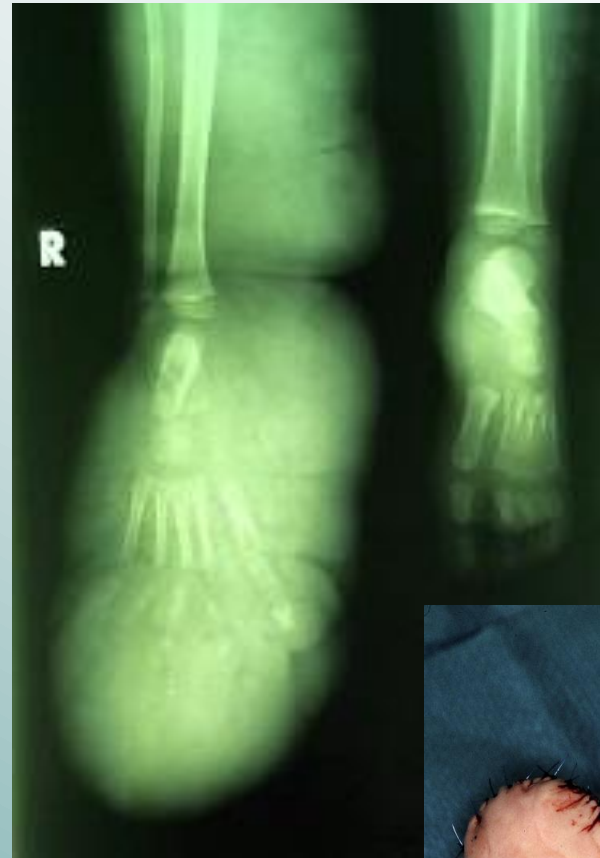
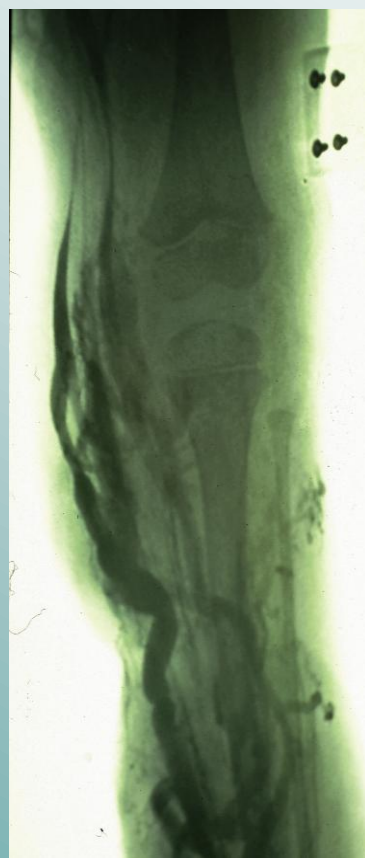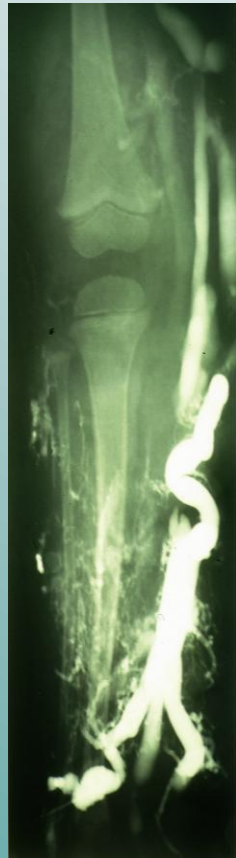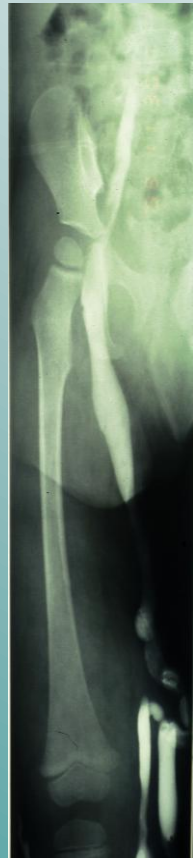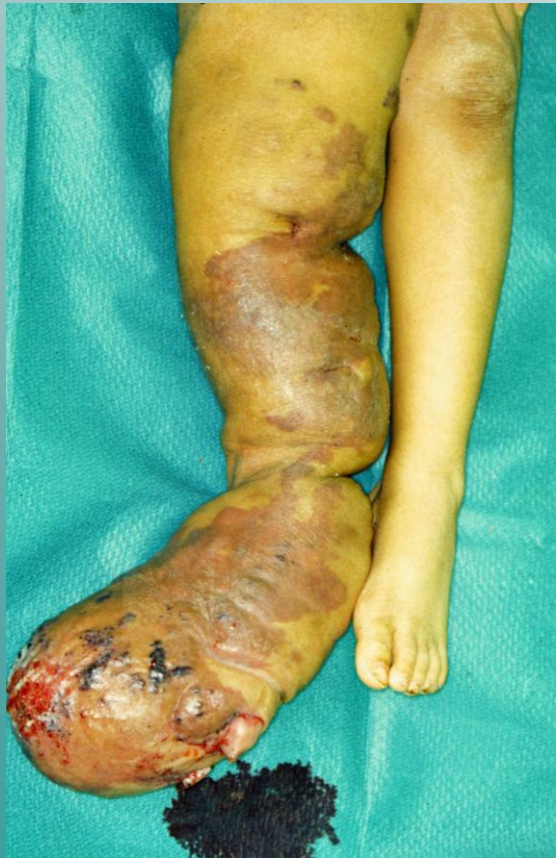age: 3 years



age: 15 years (after a further treatment elsewhere)

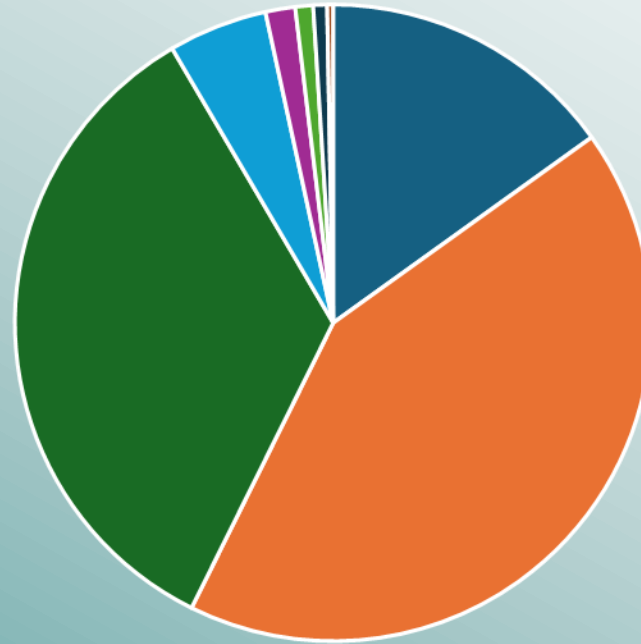
Complex hemolymphatic malformation of the right foot and shank



Situation after vascular surgery
and plastic surgery

Long Follow-Up Results in Surgical Treatment of Vascular Malformations. A Review of 1378 Cases (Multicenter Study of 4 Centres), 2001

D.A. Loose, S. Belov, R. Matassi, M. Vaghi, G. Tasnádi and A. Rehder



- Excellent 15%
- Good 42%
- Improvement 34%
- Relapse 5%
- No change 1,5%
- Worsening 0,9%
- Amputation 0,7%
- Exitus 0,3%

Our “Interdisciplinary Centre of the Diagnosis and Treatment of congenital vascular Malformations” in Hamburg currently serves a patient base consisting of about 2,000 individuals since 1974.



Con cordiali saluti da Amburgo,
vi ringrazio per l'attenzione !!